



How Surgery Affects Patients with Jaw Osteonecrosis? A Quality of Life Analysis Study

Çene Kemiği Osteonekrozlu Hastalarda Cerrahinin Yeri Nedir? Bir Yaşam Kalitesi Analizi Çalışması

Ahmet Biçer, Nargız İbrahimli, Ozan Can Canbolat, Tahir Gürler

Ege University Faculty of Medicine, Department of Plastic, Reconstructive, and Aesthetic Surgery, İzmir, Turkey

Abstract

Objective: Osteonecrosis of the jawbone, especially when associated with osteomyelitis, is a debilitating condition predominantly affecting patients treated for osteoporosis, cancer with bone metastases, and rheumatoid arthritis. Oral pathologies may significantly alter the patients' quality of life and sense of health. Surgery including complete debridement of the necrotic bone followed by packing the dead space with antiseptic agents and meticulous repair of the overlying mucosa is gaining popularity on conservative treatment options.

Materials and Methods: In this before and after study 11 patients referred to our clinic between 2018 and 2020 with a diagnosis of maxillary or mandibular osteonecrosis with complete preoperative and postoperative analyses available were included. The patients were assessed with General Oral Health Assessment (GOHA) index preoperatively and postoperatively. These scores were compared with each other to exhibit the effect of our surgical strategy, which also outlined. The effects of patients' demographic and medical backgrounds on the quality of life were also investigated.

Results: Neither demographic, nor medical backgrounds of the patients were not found to significantly alter the GOHA index scores of the patients ($p>0.05$). However, surgical treatment was found to significantly improve the scores (preoperative mean: 38.87, \pm 6.44; postoperative mean: 31.0, \pm 8.28; $p<0.05$).

Conclusion: To obtain optimal results in the management of the patients with jawbone osteonecrosis, the treatment strategy should be based on the patient characteristics and careful radiographical examinations. Alterations of predisposing medications and introduction of proper antibiotics in the setting of associated osteomyelitis should be made before surgery. Oral/dental rehabilitation should be started immediately after mucosal healing is assured.

Keywords: Osteonecrosis, jawbone osteonecrosis, osteomyelitis, bisphosphonates

Öz

Amaç: Çene kemiklerinin osteonekrozu, özellikle kanser, romatoid artrit ve osteoporoz hastalarının tedavileriyle ilişkili olarak da ortaya çıkabilen, yaşam kalitesini önemli ölçüde düşürebilen bir hastalıktır. Son yıllarda nekrotik kemiğin total rezeksiyonu, ölü boşluğun antiseptik malzemelerle doldurulması ve mukozanın dikkatlice onarılmasını içeren cerrahi tedavi seçeneği konservatif tedavilere göre daha tercih edilmiş olmuştur.

Gereç ve Yöntem: Bu öncesi ve sonrası çalışmasında kliniğimize 2018 ve 2020 yılları arasında başvuran ve preoperatif ve postoperatif değerlendirmeleri tamamlanmış 11 hasta dahil edilmiştir. Hastalar ameliyat öncesi ve sonrasında Genel Oral Sağlık Değerlendirme (GOHA) indeksi kullanılarak değerlendirilmiştir. Ameliyat öncesi ve sonrası skorlar cerrahi tedavinin etkinliğinin ortaya konması için karşılaştırılmıştır. Bunun yanında hastaların demografik ve medikal arka planlarının bu skorlara etkisi de araştırılmıştır.

Bulgular: Hastaların demografik ve medikal arka planlarının preoperatif ve postoperatif GOHA indeksi skorlarına istatistik olarak anlamlı etkilerinin olmadığı gözlenmiştir ($p>0.05$). Bununla birlikte, cerrahi tedavi sonrası hastaların GOHA indeksi skorlarında istatistik olarak anlamlı bir düşüş gözlenmiştir (preoperatif ortalama: 38,87, \pm 6,44; postoperatif ortalama: 31,0, \pm 8,28; $p<0,05$).

Sonuç: Çene kemiklerinde osteonekroz ile başvuran hastaların tedavisinde optimum bir sonuç elde edebilmek için hastaların bireysel özellikleri ve radyografik görüntüleri göz önüne alınarak bireysel bir tedavi stratejisi geliştirmek gerekir. Cerrahi öncesinde varsa etiyolojide yer alan medikasyonların düzenlenmesi ve osteomyelit eşliği durumunda ise uygun antibiyotiklerin başlanması gerekir. Postoperatif dönemde ise mukozal iyileşmenin sağlanabildiği anda erken dönemde oral ve dental rehabilitasyonun başlanması önemlidir.

Anahtar kelimeler: Osteonekroz, çene osteonekrozu, osteomyelit, bisfosfonatlar

Introduction

Spontaneous osteonecrosis of the maxilla and mandible is a painful and debilitating condition regarded as a rare phenomenon before the turn of the 21st century. However, a huge rise in incidence is observed since the early 2000s (1). This phenomenon is mostly associated with intravenous bisphosphonate use in oncologic patients with bone metastases (2). Intravenous powerful bisphosphonates are used to retain bone mineral quantity and prevent subsequent hypercalcemia associated with bone resorption. They also exert some antiangiogenic effects which may play a suppressor role in metastatic cancer (3,4).

This phenomenal peak in incidence, however, is now regarded as the second peak. Late 19th to early 20th century reports of hundreds of men working in the white phosphorus mines, and several hundreds of women working in matchstick making industry in which matchsticks were hand made by dipping sticks to flammable white phosphorus (P⁴) without proper protection. A painful jaw infection resulting in loss of bone was the result (5). Though the original name given was “phosphorimus chronicus”, the name “phossy jaw” gained popularity to describe this painful and disfiguring condition (6). The mechanism of reactant phosphorus fume causing toxic effects is related to formation of bisphosphonate species in the presence of oxygen, water, and amino acids like lysine (5). Osteonecrosis resulting from medical use of the bisphosphonates is sometimes called “bisphossy jaw” to relate these infamous victims of phosphorus industry (6,7). Besides bisphosphonates, other proponents of jaw osteonecrosis include radiotherapy, anti-angiogenic agents, or novel drugs addressing osteoclastic activity such as denosumab (8). As per the current American Association of Oral and Maxillofacial Surgeons’ perspective a diagnosis of “medication-related osteonecrosis of the jaw” can be established provided that these three criteria are met: i) patient currently under treatment with antiresorptive or antiangiogenic agents, ii) bony exposure either through an open wound or a sinus, and iii) no history of previous radiotherapy or metastasis to the affected bone (9).

Spontaneous jaw osteonecrosis without previously mentioned culprits, however, is rarely documented in the literature. It is associated with osteomyelitis and almost always require some degree of local or generalized immunodeficiency (10). It is best to keep in mind that medication-related osteonecrosis is also associated with osteomyelitis and antibiotics are still among the first line treatments in reverting the condition (11,12).

Treatment aims to control pain, improve quality of life, control the progression of bone loss, and revert infection (13). Medical treatment options include local and systemic antimicrobials as infection, either as a concomitant or as a causative point of view, is closely intertwined with the disease (14-17).

Pentoxifylline, an oral xanthin derivative used in patients with peripheral vascular disease for its hemorheological, anti-aggregation, and blood viscosity reducing effects is found to be successful in both palliation of the claudication and in halting

the disease progression. It is often combined with vitamin E, antimicrobials, and clodronate (the so-called PENTOCLO protocol) (18-20). Human recombinant parathormone, teriparatide is also used with variable reported outcomes from complete resolution to refractoriness (21,22). Hyperbaric oxygen therapy is also used mostly in adjunct to other treatment modalities (12).

Surgical treatment options include complete resection or curettage of the necrotic bone, and covering the wound with mucosa of excellent viability (23-25).

In this “before and after” study, patients with spontaneous osteonecrosis of the jaw were assessed. The authors sought for level three evidence for the effectivity of surgical treatment in patients with the condition, albeit with different etiologic and demographic backgrounds.

Materials and Methods

This study is approved by the Ege University Ethics Committee with the date 08.11.2021 and approval number 21-11T/26. Eleven patients who were referred to our clinic between 2019 and 2020 with a diagnosis of osteonecrosis of the jaw were enrolled in this study. Written consent forms have been obtained from each of the patients for both surgery and anticipation in the study protocols. Three of these patients were lost to follow up (two of them died of unrelated causes, and we were not able to contact with one of them). Remaining eight patients were included in the study.

Surgical techniques used to treat the patients were selected based on preoperative assessments including history/etiology, clinical examination, radiological examination, scintigraphy, and blood tests. The surgical treatment was carried out under general anesthesia with nasotracheal intubation, in combination with infiltration of the lower gingivobuccal sulcus near the affected site with lidocaine/adrenaline solution. Complete debridement of the necrotic bone and soft tissue, complete curettage of cysts, and extirpation of involved teeth and roots was sought. Whenever necessary, a segmentary resection followed by reconstruction or osteosynthesis and intermaxillary fixation were done. Remaining healthy bone tissue was soaked with either hydrogen peroxide (5%) or iodoform powder. This step was followed by jet lavage with normal saline solution and packing with absorbable sponge packs. The incisions were then closed with interrupted 4/0 poliglecaprone sutures. A chin-to-vertex bandage was applied to limit edema formation and hemorrhage. The bandages were discontinued one week after the operation. Figure 1 summarizes the decision-making process involving jawbone osteonecrosis in our institution (Figure 1).

Age, sex, educational background, presence of previous dental treatment, prosthetic denture use, etiologic factors, general health status, affected anatomical location, presence of osteomyelitis and type of surgery were recorded. In order to assess the oral functions, the General Oral Health Assessment (GOHA) index was used before, and at least three weeks after surgery (26,27).

Statistical Analysis

Statistical analyses were conducted using SPSS v 25 program. Parametric tests were used as recorded index scores marginally passed diagnostic tests for normality. For independent sample comparisons of mean preoperative/postoperative indices when samples were grouped according to sex, presence of a known etiology, or coexistence of osteomyelitis; independent samples Student t-test (ANOVA in cases where more than two groups were compared) was used. Matched pair comparisons of the patients' mean preoperative and postoperative indices were made using the paired samples t-test. Correlation of the age with the index scores were assessed using Pearson correlation test. Statistical significance level was set at 0.05.

Results

Demographic overview of the operated patients is presented in Table 1. Mean age of the patients was 54.5 (+/- 19.8). Mean

follow-up was 15.7 weeks (+/- 19.4). Female to male ratio was 1/1. Educational level of the patients was comparable to the general population (Table 1).

Etiological factors included previous radiotherapy to head and neck (one patient) and bisphosphonate use (four patients). In three patients no etiological factor could be identified. Etiological factors, preoperative prosthetic use, anatomical location of the lesion, presence of concurrent osteomyelitis, and surgical approach selected were not significantly affected preoperative or postoperative GOHA index scores ($p>0.05$) (Table 2).

On the other hand, surgical therapy significantly alleviated the oral functions of the patients as per measured by the GOHA index. Preoperative mean GOHA index score was 38.9 (+/- 6.4), and postoperative mean score was 31.0 (+/- 8.3). The difference between the mean scores were statistically significant ($p<0.05$; the GOHA index scores and medical background of the patients were given in Table 2).

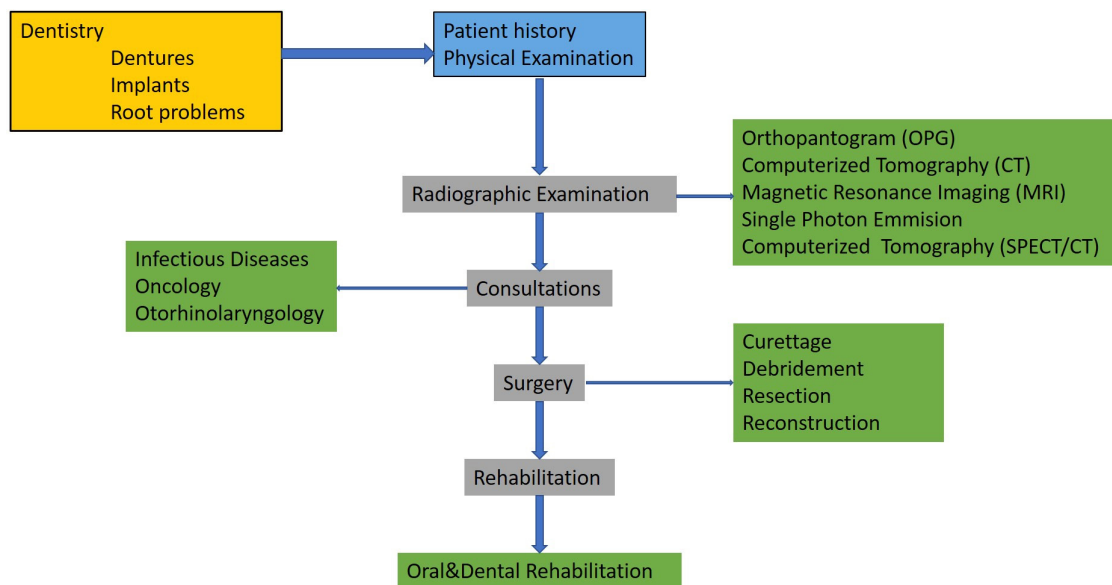


Figure 1. Decision making process of our institution when a patient is referred with a preliminary diagnosis of jawbone osteonecrosis. If a patient admits to our clinic before any consultation from dentistry, they are assured to have one before moving on with the flow chart

Table 1. Demographic overview of the patients

Demographic data	Descriptive; mean, standard deviation, frequencies		Comparison of GOHA scores
Age	54.5 (+/- 19.8)		$p>0.05^a$, $r=-0.590$ $p>0.05^a$, $r=0.082$
Sex	Female	4	$p>0.05^b$ $p>0.05^b$
	Male	4	
Education	Primary education	2	$p>0.05^c$ $p>0.05^c$
	Secondary education	4	
	Tertiary education	2	

GOHA: General Oral Health Assessment, statistical tests used: ^aPearson correlation test, ^bIndependent samples Student t-test, ^cANOVA test

Table 2. Medical and surgical characteristics of the patients. GOHA index scores obtained preoperatively and postoperatively

Disease characteristics	Descriptive; mean, standard deviation, frequencies		Comparison of GOHA scores
Etiology	Radiotherapy	1	p>0.05 ^c p>0.05 ^c
	Bisphosphonate use	4	
	Idiopathic	3	
Prosthetic use	Yes	3	p>0.05 ^d p>0.05 ^d
	No	5	
Anatomical location	Alveolar process	2	p>0.05 ^c p>0.05 ^c
	Symphysis	1	
	Corpus	3	
	Angulus	2	
Operative approach	Curettage	4	p>0.05 ^c p>0.05 ^c
	Debridement	3	
	Resection/osteosynthesis	1	
Osteomyelitis	Yes	6	p>0.05 ^d p>0.05 ^d
	No	2	
Histopathology*	Osteomyelitis	6	p>0.05 ^c p>0.05 ^c
	Osteonecrosis	5	
	Osteosclerosis	1	
GOHA index		Descriptive	Statistical significance
	Preoperative	38.9 (+/-6.4)	p=0.018 ^e
	Postoperative	31.0 (+/-8.3)	

GOHA: General Oral Health Assessment, statistical tests used: ^aANOVA test, ^dIndependent samples Student t-test, ^epaired samples t-test.
*Some patients presented with more than one pathology

Discussion

This study confirms that the primary treatment of osteonecrosis of the jawbones is surgical. Conservative treatment with systemic antibiotics should be reserved for patients with symptomatic acute infection, or acute exacerbation of a chronic infection. Nevertheless, antibiotherapy should be followed by complete surgical extirpation of the affected bone if complete remission is aimed.

One of the critical aspects of complete treatment of patients with jawbone osteonecrosis is employing a harmonious teamwork. Preoperative and postoperative dental assessment is pivotal. If the patient is edentulous, proper use of prosthetics should be warranted (28). Niiibe et al. (29) found that prosthetic use is a significant factor in development of jaw osteonecrosis in patients under bisphosphonate or denosumab therapy. Postoperative oral and dental rehabilitation, albeit commenced cautiously is of paramount importance to these patients' endeavors in regaining their life quality. However, it is recommended to wait until complete mucosal healing is achieved (Figure 2), especially if the exact region or neighboring bone is to be utilized for prosthetic support (30,31). Timely consultations with infectious diseases not only aids in overcoming painful acute exacerbations of oral infections, but also helps establishing a good clinical practice avoiding evolution of resistant strains, especially in the hospital

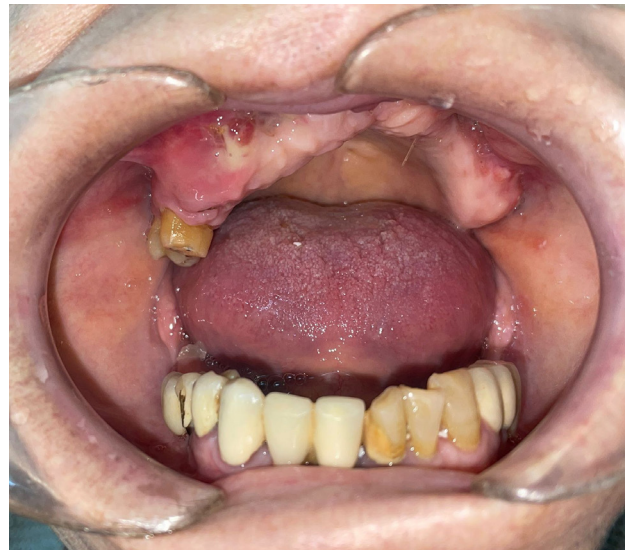

Figure 2. Dental rehabilitation is commenced after complete mucosal healing is achieved postoperatively

setting (Figure 3A, B). Haeffs et al. (32) found that jawbone region is a high risk region for resistant strains to breed. Although some authors found surgical therapy somewhat futile for patients especially with concomitant medical conditions and/or patients with old age as life expectancy is low (33), others

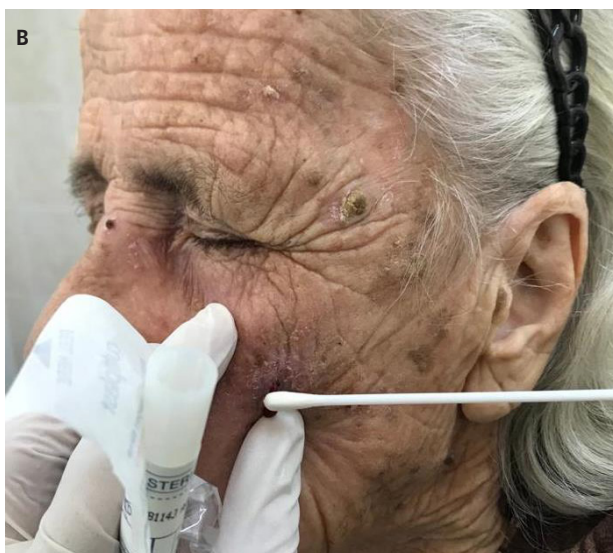
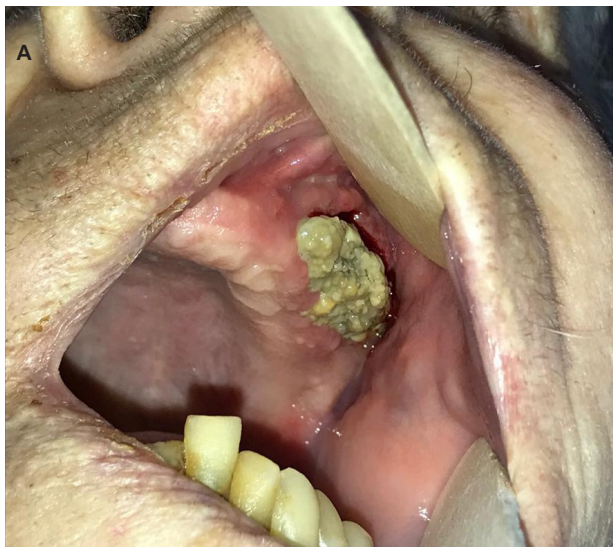argued that the life expectancy may not be that low, if the patients are selected carefully (34). As we only lost two patients in the follow up, we believe that every effort should be made to effectively treat this patient group.

Proper selection of surgical technique and resection margins relies on proper preoperative radiological analyses (35). In the case of osteomyelitis setting, X-ray radiographs lack sensitivity (35). However, we find orthopantomograms especially useful for assessing the necrotic bone/healthy bone transition with high definition in patients with osteonecrosis. Computed tomography (CT) scans add even more resolution and are especially invaluable in surgical planning (36) (Figure 4A, B). Single-photon emission CT, as well as magnetic resonance imaging have higher accuracy in diagnosing concurrent osteomyelitis (Figure 5), unless the disease is at its very early stages (37). For differential

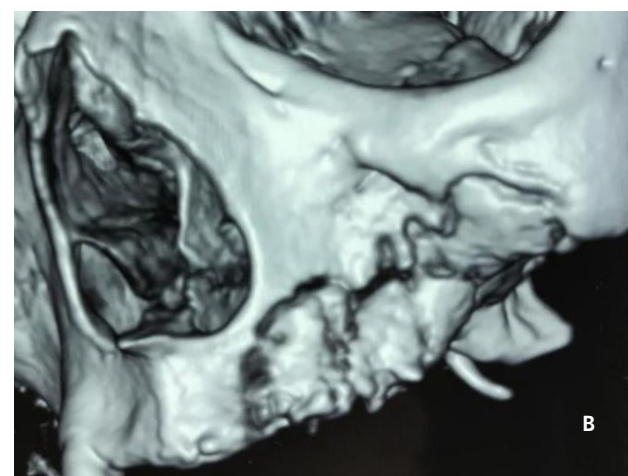
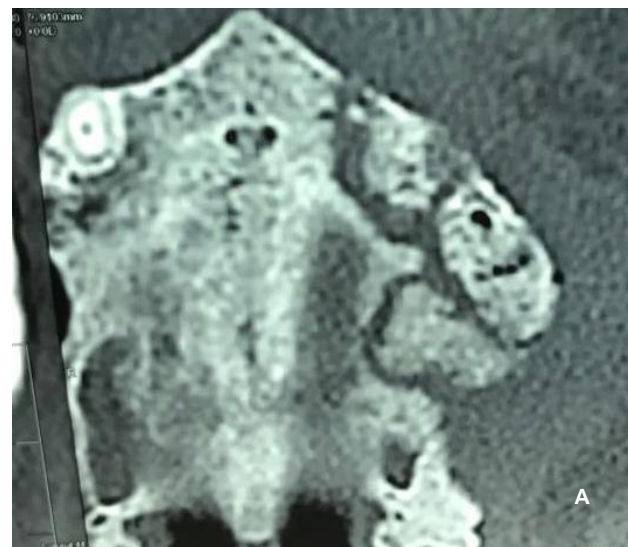diagnosis of chronic osteomyelitis ongoing for over six months, fluorodeoxyglucose-positron emission tomography can be indicated (35).

Use of GOHA as a self-reported questionnaire instead of more detailed methods had its advantages such as practicality, and repeatability. Lim et al. (38) found this aspect particularly helpful for the old age group. GOHA index is a validated tool in assessing the oral health status of a cross section of population (26). Impact of oral health on general well-being, either physical or psychological is irrefutable (39).

Major shortcomings of the study are small number of patients, lack of a control group, and single dimension assessment tool used. The reasons behind this can be as follows: as awareness of dental and other health professionals increase regarding the relationship of bisphosphonate use and dentoalveolar problems, the number of patients tend to decline. Another point is that most of the patients in this group is of old age. Even though



Figures 3A, B. Oral inspection of a patient with maxillary alveolar osteonecrosis (3A). Same patient concurrently has osteomyelitis accompanied with cheek skin fistulation (3B). Preoperative consultation with infectious diseases along with a microbiological culture is crucial to treat this combination



Figures 4A, B. Computerized tomography (CT) is a very useful tool in an effort to outline the level of resection preoperatively (4A). 3D rendering of the thin slice CT sections may also prove to be useful in this aspect (4B)

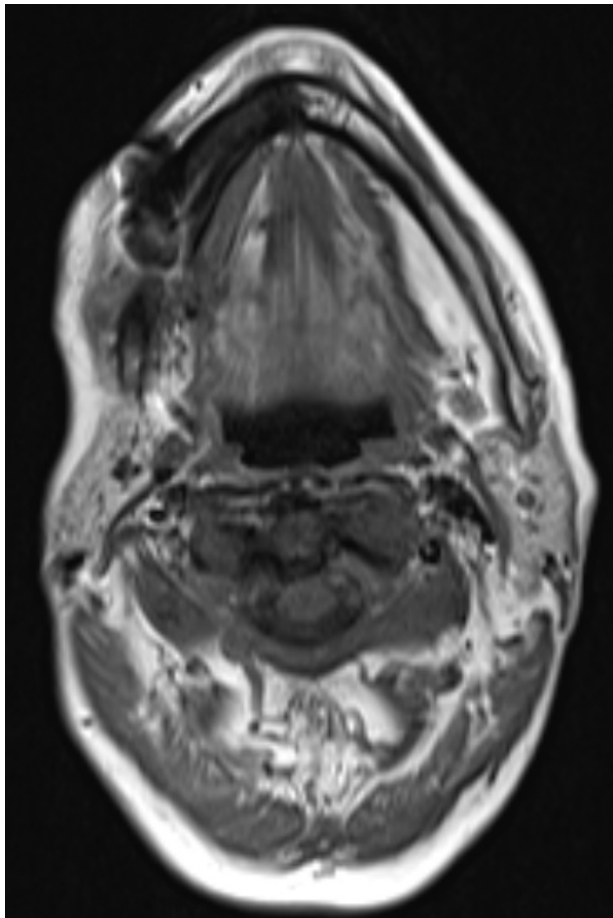


Figure 5. Magnetic resonance imaging can effectively differentiate osteomyelitis and bone metastasis in this patient. A linear contrast uptake in the periphery of the lesion with necrotic core suggested osteonecrosis accompanied with osteomyelitis. The lesion showed lower intensity in diffusion images unlike multiple metastatic lesions in the skull base and cervical vertebrae

mortality rate was not as high, mental condition of some of the patients precluded utilization of the questionnaire. This also clarifies the lack of motivation for using additional or more comprehensive assessment tools. Older patients in our study group were particularly evasive when it came to filling long questionnaire forms, too.

Conclusion

Our study confirms that jaw osteonecrosis can be effectively treated with a proper surgical approach. This approach includes identifying the correct etiologic factors, previous dental health and prosthetic history of the patients, concurrent medical and surgical pathologies such as osteomyelitis or malignancy. Next, extension of the pathological bone must be accurately established. Orthopantomograms, and CT scans are helpful tools for surgical planning in this context. This is followed by a definitive surgical plan including complete resection of the necrotic and/or pathological bone. A good and reliable soft tissue coverage

with mucosal flaps paves the way for early oral dental and/or prosthetic rehabilitation which is the goal of our treatment regimen.

Ethics

Ethics Committee Approval: This study is approved by the Ege University Ethics Committee with the date 08.11.2021 and approval number 21-11T/26.

Informed Consent: Written consent forms have been obtained from each of the patients for both surgery and anticipation in the study protocols.

Peer-review: Internally peer-reviewed.

Authorship Contributions

Surgical and Medical Practices: A.B., O.C.C., N.İ., T.G., Concept: A.B., Design: A.B., T.G., Data Collection or Processing: O.C.C., N.İ., Analysis or Interpretation: A.B., Literature Search: A.B., Writing: A.B.

Conflict of Interest: No conflict of interest was declared by the authors.

Financial Disclosure: The authors declared that this study has received no financial support.

References

1. Marx RE. Pamidronate (Aredia) and zoledronate (Zometa) induced avascular necrosis of the jaws: A growing epidemic J Oral Maxillofac Surg 2003;61:1115-7.
2. Ruggiero SL, Mehrotra B, Rosenberg TJ, Engroff SL. Osteonecrosis of the Jaws Associated with the Use of Bisphosphonates: A Review of 63 Cases. J Oral Maxillofac Surg 2004;62:527-34.
3. Migliorati CA. Bisphosphonates and oral cavity avascular bone necrosis. J Clin Oncol 2003;21:4253-4.
4. Wood J, Bonjean K, Ruetz S, Bellahcène A, Devy L, Foidart JM, et al. Novel antiangiogenic effects of the bisphosphonate compound zoledronic acid. J Pharmacol Exp Ther 2002;302:1055-61.
5. Marx RE. Uncovering the Cause of "Phossy Jaw" Circa 1858 to 1906: Oral and Maxillofacial Surgery Closed Case Files-Case Closed. J Oral Maxillofac Surg 2008;66:2356-63.
6. Jacobsen C, Zemmann W, Obwegeser JA, Grätz KW, Metzler P. The phosphorous necrosis of the jaws and what can we learn from the past: A comparison of "phossy" and "bisphossy" jaw. Oral Maxillofac Surg 2014;18:31-7.
7. Pollock RA, Brown TW Jr, Rubin DM. "Phossy Jaw" and "Bisphossy Jaw" of the 19th and the 21st Centuries: The Diuturnity of John Walker and the Friction Match. Craniomaxillofac Trauma Reconstr 2015;8:262-70.
8. Ogura I, Minami Y, Ono J, Kanri Y, Okada Y, Igarashi K, et al. CBCT imaging and histopathological characteristics of osteoradionecrosis and medication-related osteonecrosis of the jaw. Imaging Sci Dent 2021;51:73-80.
9. Ruggiero SL, Dodson T, Fantasia J, Goodday R, Aghaloo T, Mehrotra B, et al. Definition of medication-related osteonecrosis of the jaw in 2014. Cancer 2021;1938-56. (doi.org/10.32388/520845).
10. Nezafati S, Ghavimi MA, Yavari AS. Localized osteomyelitis of the mandible secondary to dental treatment: report of a case. J Dent Res Dent Clin Dent 2009;3:67-9.
11. Senel FC, Saracoglu Tekin U, Durmus A, Bagis B. Severe Osteomyelitis of the Mandible Associated With the Use of Non-Nitrogen-Containing Bisphosphonate (Disodium Clodronate): Report of a Case. J Oral Maxillofac Surg 2007;65:562-5.

12. Williams WB, O’Ryan F. Management of Medication-Related Osteonecrosis of the Jaw. *Oral Maxillofac Surg Clin North Am* 2015;27:517-25.
13. Ruggiero SL, Dodson TB, Fantasia J, Goodday R, Aghaloo T, Mehrotra B, et al. American association of oral and maxillofacial surgeons position paper on medication-related osteonecrosis of the jaw - 2014 update. *J Oral Maxillofac Surg* 2014;72:1938-56.
14. Hinson AM, Smith CW, Siegel ER, Stack BC Jr. Is bisphosphonate-related osteonecrosis of the jaw an infection? A histological and microbiological ten-year summary. *Int J Dent* 2014;2014:452737.
15. De Ceulaer J, Tacconelli E, Vandecasteele SJ. Actinomyces osteomyelitis in bisphosphonate-related osteonecrosis of the jaw (BRONJ): the missing link? *Eur J Clin Microbiol Infect Dis* 2014;33:1873-80.
16. Moretti F, Pelliccioni GA, Montebugnoli L, Marchetti C. A prospective clinical trial for assessing the efficacy of a minimally invasive protocol in patients with bisphosphonate-associated osteonecrosis of the jaws. *Oral Surg Oral Med Oral Pathol Oral Radiol Endod* 2011;112:777-82.
17. Kumar SK, Gorur A, Schaudinn C, Shuler CF, Costerton JW, Sedghizadeh PP. The role of microbial biofilms in osteonecrosis of the jaw associated with bisphosphonate therapy. *Curr Osteoporos Rep* 2010;8:40-8.
18. Robard L, Louis MY, Blanchard D, Babin E, Delanian S. Medical treatment of osteoradionecrosis of the mandible by PENTOCLO: Preliminary results. *Eur Ann Otorhinolaryngol Head Neck Dis* 2014;131:333-8.
19. Delanian S, Chatel C, Porcher R, Depondt J, Lefaix J. Complete restoration of refractory mandibular osteoradionecrosis by prolonged treatment with a pentoxifylline-tocopherol-clodronate combination (PENTOCLO): A phase II trial. *Int J Radiat Oncol Biol Phys* 2011;80:832-9.
20. Epstein MS, Wicknick FW, Epstein JB, Berenson JR, Gorsky M. Management of bisphosphonate-associated osteonecrosis: Pentoxifylline and tocopherol in addition to antimicrobial therapy. An initial case series. *Oral Surg Oral Med Oral Pathol Oral Radiol Endod* 2010;110:593-6.
21. Ohbayashi Y, Miyake M, Sawai F, Minami Y, Iwasaki A, Matsui Y. Adjunct teriparatide therapy with monitoring of bone turnover markers and bone scintigraphy for bisphosphonate-related osteonecrosis of the jaw. *Oral Surg Oral Med Oral Pathol Oral Radiol* 2013;115:31-7.
22. Narváez J, Narváez JA, Gómez-Vaquero C, Nolla JM. Lack of response to teriparatide therapy for bisphosphonate-associated osteonecrosis of the jaw. *Osteoporos Int* 2013;24:731-3.
23. Markose G, Mackenzie FR, Currie WJ, Hislop WS. Bisphosphonate osteonecrosis: a protocol for surgical management. *Br J Oral Maxillofac Surg* 2009;47:294-7.
24. Heufelder MJ, Hendricks J, Remmerbach T, Frerich B, Hemprich A, Wilde F. Principles of oral surgery for prevention of bisphosphonate-related osteonecrosis of the jaw. *Oral Surg Oral Med Oral Pathol Oral Radiol* 2014;117:429-35.
25. Wilde F, Heufelder M, Winter K, Hendricks J, Frerich B, Schramm A, et al. The role of surgical therapy in the management of intravenous bisphosphonates-related osteonecrosis of the jaw. *Oral Surg Oral Med Oral Pathol Oral Radiol Endod* 2011;111:153-63.
26. Niesten D, Witter D, Bronkhorst E, Creugers N. Validation of a Dutch version of the Geriatric Oral Health Assessment Index (GOHAI-NL) in care-dependent and care-independent older people. *BMC Geriatr* 2016;16:53.
27. Campos JADB, Zucoloto ML, Bonafé FSS, Maroco J. General Oral Health Assessment Index: A new evaluation proposal. *Gerodontology* 2017;34:334-42.
28. Saldanha S, Shenoy VK, Eachampati P, Uppal N. Dental implications of bisphosphonate-related osteonecrosis. *Gerodontology* 2012;29:177-87. (<https://pubmed.ncbi.nlm.nih.gov/22486711/>). (Accessed September 18, 2021)
29. Niibe K, Ouchi T, Iwasaki R, Nakagawa T, Horie N. Osteonecrosis of the jaw in patients with dental prostheses being treated with bisphosphonates or denosumab. *J Prosthodont Res* 2015;59:3-5.
30. Rugani P, Kirnbauer B, Acham S, Truschnegg A, Jakse N. Implant placement adjacent to successfully treated Bisphosphonate-related Osteonecrosis of the jaw (BRONJ) *J Oral Implantol* 2015;41:377-81.
31. Kim JW, Baik J, Jeon JH. Dental implant treatment after healing of bisphosphonate-related osteonecrosis of the jaw (BRONJ) in the same region: a case report. *J Korean Assoc Oral Maxillofac Surg* 2016;42:157-61.
32. Haefls TH, Scott CA, Campbell TH, Chen Y, August M. Acute and Chronic Suppurative Osteomyelitis of the Jaws: A 10-Year Review and Assessment of Treatment Outcome. *J Oral Maxillofac Surg* 2018;76:2551-8.
33. Lazarovici TS, Yahalom R, Taicher S, Elad S, Hardan I, Yarom N. Bisphosphonate-Related Osteonecrosis of the Jaws: A Single-Center Study of 101 Patients. *J Oral Maxillofac Surg* 2009;67:850-5.
34. Bedogni A, Saia G, Bettini G, Tronchet A, Totola A, Bedogni G, et al. Long-term outcomes of surgical resection of the jaws in cancer patients with bisphosphonate-related osteonecrosis. *Oral Oncol* 2011;47:420-4.
35. Tiwari P, Bera RN, Kanojia S, Chauhan N, Hirani MS. Assessing the optimal imaging modality in the diagnosis of jaw osteomyelitis. A meta-analysis. *Br J Oral Maxillofac Surg* 2021;59:982-92.
36. Gönen ZB, Yillmaz Asan C, Zararsiz G, Kiliç E, Alkan A. Osseous changes in patients with medication-related osteonecrosis of the jaws. *Dentomaxillofac Radiol* 2018;47: 20170172.
37. Reinert S, Widlitzek H, Venderink DJ. The value of magnetic resonance imaging in the diagnosis of mandibular osteomyelitis. *Br J Oral Maxillofac Surg* 1999;37:459-63.
38. Lim J, Park H, Lee H, Lee E, Lee D, Jung HW, et al. Longitudinal impact of oral health on geriatric syndromes and clinical outcomes in community-dwelling older adults. *BMC Geriatr* 2021;21:482.
39. Kandelman D, Petersen PE, Ueda H. Oral health, general health, and quality of life in older people. *Spec Care Dentist* 2008;28:224-36.